

# Bone augmentation using CGF-a Case report with two year follow up.

Prof Dr. Rakshith Hegde\*, Dr. Nivya John\*\*, Dr. Manoj Shetty+, Dr. Prathul Kumar++

### Abstract

Successful implant treatment requires: Primary stability at placement Integration in a prosthodontically driven position Careful management of the living bone. Bone volume may be inadequate to completely embed the implant Incompletely covered implants may result in complication soft tissue recession inflammation and infection and eventual loss of implant .Bone augmentation with barrier membrane technique has proven to successful to regenerate the bone volume. Concentrated growth factors have shown promising results when used with combination of grafting materials.This case report presents a case wherein the site of implant placement has been incorporated with a mixture of cgf and allograft. A two year follow up shows good tissue thickness and volume.

### Keywords: Cgf, allograft, implants

#### Introduction

Bone augmentation with barrier membrane technique ,the concept of GBR was first described in 1959 when cell occlusive membranes were employed for spinal fusions.<sup>1</sup> A variety of non resorbable and resorbable bone grafting materials have been used in bone augmentation with GBR concept Oral Implantology. From a manufacturing aspect what we should look for is material biocompatibility ,stability over the required duration of barrier function, space maintenance ,exclusion of undesired cell ingrowth and ease of use<sup>2,3,4,5</sup>

The size of the defect also influences the bone healing capacity .In large defects the bone formation is limited to the marginal stable zone with a central zone of disorganized loose connective tissue,thus combined use of bone grafts or bone replacements substitute with cell occlusive barrier membranes are advocated in bone regeneration of larger defects.One such example is eptfe membranes which is

considered a standard for bone augmentation. However soft tissue dehiscence is a common complication.<sup>6,7</sup>

Thus bio resorbable membranes were developed. Although these membranes also elicit soft tissue inflammation and soft tissue dehiscence, the communication with the oral cavity accelerates resorption rate thus reduces the contamination of the regenerated bone matrix.<sup>8,9</sup>

Variety and contemporary surgical procedures and dental materials available for reconstruction of body defects and concentrated growth factors is one of the risk-free procedures. Growth Factors are mediators which regulate key processes like tissue regeneration, including cell proliferation and differentiation, synthesis of extracellular matrix, chemotaxis and angiogenesis. Thrombocytes play a major role in repairing of mineralized and soft tissues. The latest approach to Guided Bone Regeneration and Augmentation of the lost bony structures of alveolar ridge is

application of the fibrin rich block with concentrated growth factor.<sup>10</sup>

The following case report depicts a case with anterior missing teeth and was rehabilitated with hard tissue augmentation using CGF mixed allograft and immediate implant placement.

**Case report:**

A young patient presented with missing upper front teeth to the department of Oral Implantology. The history revealed that the cause of loss of teeth was traumatic injury. After Oral prophylaxis and endodontic scaling, patient was adviced oral implants with lateral augmentation.(figure 1,2)

The patient was pharmacologically managed with prophylactic and therapeutic dose of antibiotics.(amoxicillin 500mg).

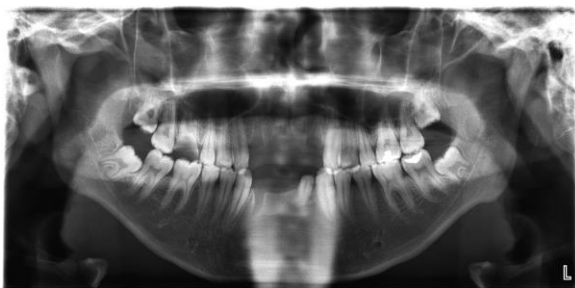


Figure 1: PRE OPERATIVE OPG

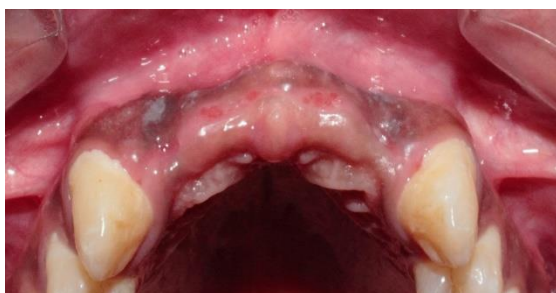

Figure 2: PREOPERATIVE INTEROCCLUSAL VIEW

On the day of surgery, collection of venous blood (saccos protocol) was done from superficial vein with a 21-gauge needle with all the blood counts in normal range. 9 mL of blood was drawn into each sterile Vacutainer blood collection tube (Greiner Bio-One, GmbH, Kremsmunster, Austria) silicon coated as a serum clot activator. These tubes were then immediately centrifuged in a special machine (Medifuge MF200, Silfradent srl, Forlì, Italy) using a program with the following characteristics: 30 seconds acceleration, 2 minutes at 2,700 rpm, 4 minutes at 2,400 rpm, 4 minutes 2,700 rpm, 3 minutes at 3,000 rpm and 36 seconds deceleration and stopped.

At the end of the process, three blood fractions were identified(figure 3): (1) the upper layer, representing the liquid phase of plasma named platelet poor plasma (PPP), (2) the lower layer, at the bottom of the tube, consisting in free red blood cells (RBC); (3) the middle layer, representing the solid CGF<sup>10</sup>

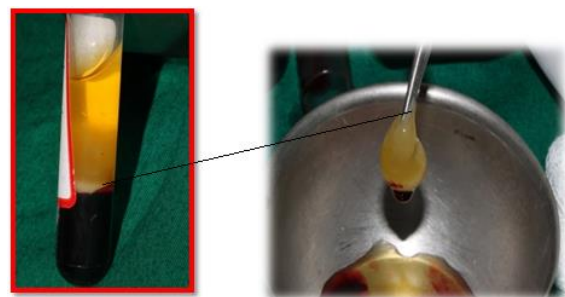


Figure 3: CGF collection from patient venous blood

The placement of implant was conducted in a sterile operating theatre.

Disinfection of the facial skin was done using Povidone – Iodine Solution IP (Betadine) paint. Patient was given an oral mouth rinse, Induction of local anaesthesia

was carried out using Lignospan special (2% lidocaine with 1:80,000 Adrenaline) .

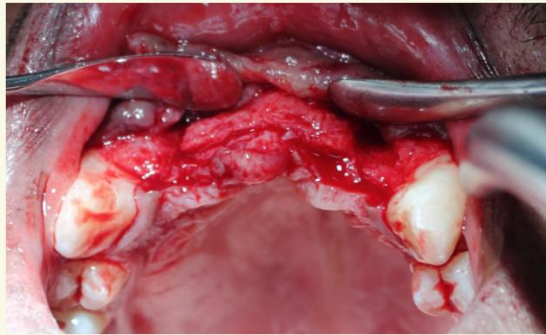


Figure 4:flap elevation

After a full thickness flap elevation (Figure 4). A 2 mm pilot drill was used to mark the initial osteotomy sites. Paralleling pin was used to check the parallelism and depth of the osteotomy site. A 3.2mm twist drill was used next and the osteotomy widened . After the preparation of the osteotomy site, a 3.5 x 11 mm implant was placed with the help of physio-dispenser .All the implants were placed at a minimum insertion torque of 25 Ncm assessed by the physio-dispensor(Figure 5).

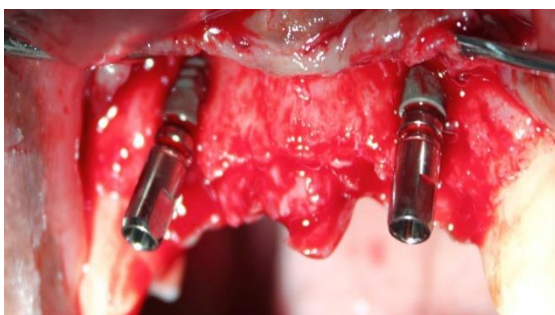


Figure 5: implant placement

CGF was removed from test tube, using sterile tweezers and was mixed with the allograft (figure 6a,6b) and then placed into the site and closure was attained using vicryl sutures.

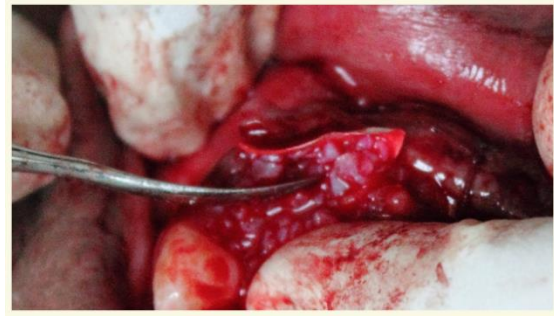


Figure 6a: graft placement

Patient was requested to revisit for suture removal and follow up check ups. Prosthetic phase began with implant level impression procedures. During the waiting period of 6 months (figure 7)sulcus former were placed to attain the gingival silhouette .At the time of fit in,the sulcus formers were removed and impression was made(figure 8) .Customised abutments were placed and torqued at 25 Ncm which is the recommended torque for implant abutment connection for Ankylos ® system A metal-ceramic bridge was fabricated which was autoclaved before cementing and was cemented using zinc-phosphate cement.(Figure 9,10a,10b)

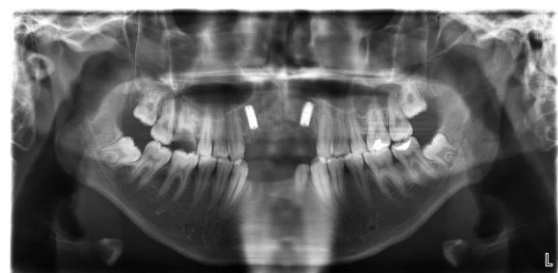


Figure 7: 6 month post operative radiographic view



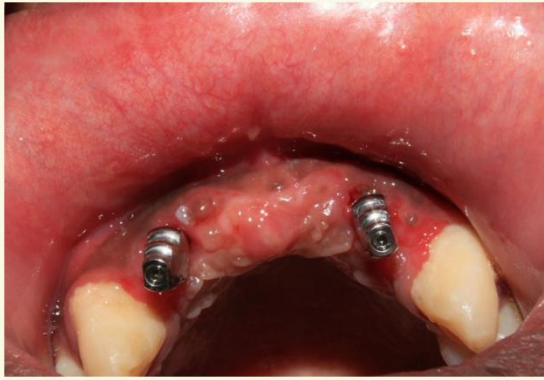

Figure 8: impression coping in place

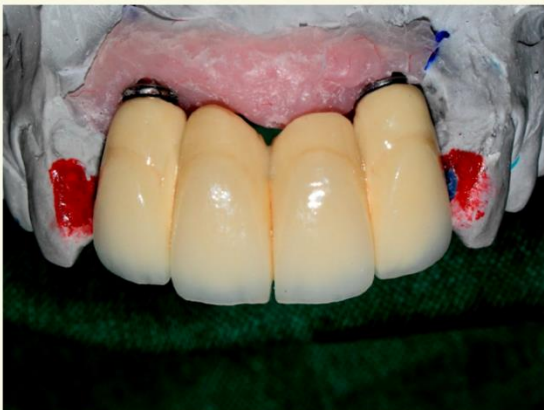

Figure 9: prosthesis

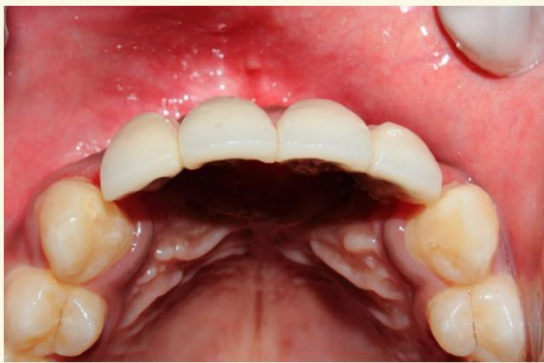

Figure 10a: fit in of the prosthesis

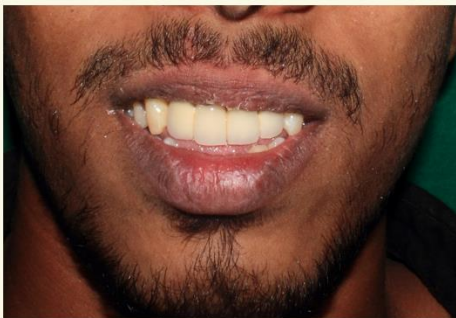


Figure 10b: smile view post cementation

Post operative radiographs(Two year follow up) revealed well seated abutment and a stable crestal bone level.(figure 11)

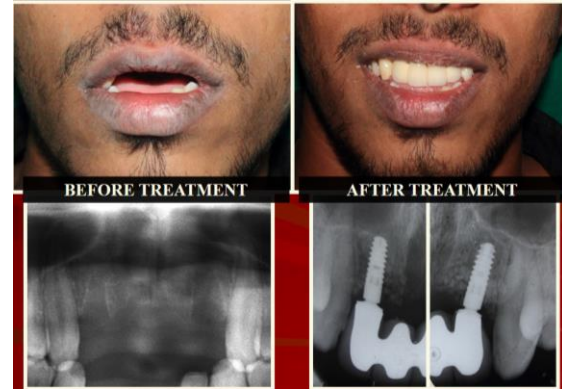


Figure 11: two year follow up

**Discussion**

When comparing the various available graft materials used with or without a membrane, Giorgio Pagni et al. In his study concluded that biomaterials such as bio-OSS and hydroxyapatite when placed in submerged situations resulted in better healing. Thus, synthetic bone graft materials are being preferred by more clinicians.

CGF, first introduced by Sacco, has recently become popular. CGF is produced by the centrifugation of venous blood as same as PRF. However, the technique is different on centrifugation speed. Unlike PRF, CGF use variable rpm from 2400-2700 rpm to separate cells in the venous blood, therefore, results in fibrin rich blocks that are much larger, denser and richer in GF than common PRF. This shows better regenerative capacity and higher versatility when using the fibrin rich block.

CGF also shows higher tensile strength, more growth factors, higher viscosity and higher adhesive strength than PRF. CGF

can act as barrier membrane to accelerate soft tissue healing or be mixed with bone graft to accelerate new bone formation.<sup>10,11</sup>

In the above mentioned patient it was decided to mix the allograft with CGF and place the graft and then further cover it up with a slow resorbable barrier membrane. Geistlich Bio-Gide® integrates with surrounding tissues to protect the initial coagulum. The bilayer structure helps in preventing ingrowth of soft tissue into the augmented site, and optimally degrades to allow for the cascade of biologic events leading to regeneration.<sup>12,13</sup>

The post operative radiographs revealed a stable crestal bone level. Patients esthetic demands were met, in spite of the excessive axiocoronal length of the bridge which was compensated by the patient's thick lips and low smile line, however, it is advised to strictly follow a prosthetically driven implant placement irrespective of the bone architecture.

### Conclusion:

This case report presented with a dental trauma that caused an edentulous anterior area. Extensive care must be taken to rehabilitate these sites especially when we suspect fractures and poor density bone. CGF provides a safe, cost effective alternative to autografts during grafting procedures. CGF can be used in other implant case scenarios that include sinus augmentation and ridge preservation. More studies about the efficiency of CGF can validate its use in the future.

### References:

1. Hurley LA, Srinichfield FE, Basset AL, et al. The role of soft tissue in

osteogenesis: An experimental study of canine spine fusions. *J Bone Joint Surg* 1959;41-A:1234-1254

2. Dahlin c, Sennerby L, Lekholm U, et al. Generation of new bone around titanium implants using a membrane technique. *Int J Oral Maxillofac implants* 1989;4:19-25
3. Nyman S, Lindhe J, Karring T, Rylander H. New attachment following surgical treatment of human periodontal disease. *J Clin Periodontol* 1982;9:290-296
4. Dahlin c, Gottlow J, Lindhe A, Nyman S. Healing of maxillary and mandibular bone defects using a membrane technique. An experimental study in monkey. *Scand J plast reconstruction surg hand surg* 1990;24:13-19
5. Buser D, Dula K, Belser U, et al. Localized ridge augmentation using guided bone regeneration. I. Surgical procedure in the maxilla. *Int J Periodontics Restorative Dent* 1993;13:29-45.
6. Buser D, Dula K, Belser UC, et al. Localized ridge augmentation using guided bone regeneration. II. Surgical procedure in the mandible. *Int J Periodontics Restorative Dent* 1995;15:10-29.
7. Simion M, Baldoni M, Rossi P, et al. A comparative study of the effectiveness of e-PTFE membranes with and without early exposure during the healing period. *Int J Periodontics Restorative Dent* 1994;14: 166-180.
8. Hurzeler MB, Kohal Rj, et al. Evaluation of new bioresorbable barrier to facilitate guided bone

- regeneration around exposed implant threads. an experimental study in the monkey. Int J Oral and Maxillofac Surg 1998;27:315-320
9. Owens KW, Yukna RA. Collagen membrane resorption in dogs: a comparative study of implant design. Int J Oral Maxillofac Surg 2001;10:49-58
  10. Manoj, S., Punit, J., Chethan, H., & Nivya, J. (2018). A study to assess the bone formed around immediate postextraction implants grafted with Concentrated Growth Factor in the mandibular posterior region. Journal of Osseointegration, 10(4), 121-129.
  11. Ana Tadic, Tatjana PUSKAR and Branislava PETRONIJEVIC. Application of fibrin rich blocks with concentrated growth factors in pre-implant augmentation procedures. Med Pregl 2014; LXVII (5-6); 177-180. Novi Sad: maj-jun
  12. Schwarz F, et al.: Clin Oral Implants Res 2006; 17: 403-09
  13. Schwarz F, et al.: Clin Oral Implants Res 2008; 19(4): 402-15.

\*- Professor, Department of Prosthodontics

\*\* - Lecturer, Department of Prosthodontics

+ - Professor and Head of Oral Implantology

++ - Tutor, Department of Oral Implantology

A B Shetty Memorial Institute of Dental Sciences,

Mangalore